Surgical Repair of Mandibular Fracture in a Newborn Calf

Sridhar Remala[1], S Bhaskara RamaRaju Sagi[2] and Srinivas Yeturi[2]
State Institute of Animal Health (SIAH)
Department of Animal Husbandry
Tanuku - 534211 (Andhra Pradesh)

Abstract

Present communication reports successful surgical correction of bilateral fracture of horizontal ramus of mandible at the interdental space in a five day old calf, caused by traction of calf during dystocia. The fracture was repaired with intramedullary pinning and hemicerclage wiring.

Keywords: Calf; fracture; mandible; surgery

www.IJour.net
Members Copy, Not for Commercial Sale
Downloaded From IP - 3.145.188.160 on dated 4-May-2024

Introduction

Fracture of mandible in bovine is rarely reported (Desrochers 2011). The most frequent presentation is following obstetrical manipulation when snare is attached to lower jaw to correct head malposition. Fractures through interdental space with involvement of horizontal ramus are the most common and usually bilateral and compound but unilateral fractures also occur. The fracture may be transverse, oblique or comminuted in nature (Tyagi and Singh, 1996). Aksoy *et al.* (2009) recorded and analysed various fractures in calves due to forced traction and mandible fractures were reported to be 10/27.

Clinical signs include downward hanging of rostral fractured fragment, misalignment of teeth, protrusion of tongue, drooling of saliva and open oral wounds with visible bone ends. Diagnosis can be made on physical examination and radiography helps to confirm fracture configuration. Both unilateral and bilateral fractures of horizontal ramus can be treated successfully using wires, pins and bone plates (Tyagi and Singh, 1996).

Orthopedic wire fixation is one of the most commonly advocated method for management of mandible fracture. However this technique has several inherent problems like unstable fixation, mal-occlusion and breakage of wire. Inspite of many complications, intramedullary pinning of mandible is preferred as it results in proper immobilization and adequate stablization necessary for anatomical and physiological restoration (Tyagi and Singh, 1996).

1. Veterinary Assistant Surgeon and Corresponding author. E-mail: srirema32@gmail.com
2. Veterinary Assistant Surgeon
a - Brand of Intas Animl Health, Ahmedabad

Clinical Presentation

A five day old male crossbred calf was presented with history of traction during its calving with clinical signs of protrusion of tongue, unable to suckle milk from mother and hanging part in rostral part of mouth (Fig. 1). Open fractures of horizontal rami of both mandibles were visible in oral cavity without any wound on ventral aspect. Radiography revealed complete bilateral fracture of horizontal rami of mandible in interdental space (Fig. 3).

Fig. 1: Tongue protrusion

Fig. 2: Visible bone ends of fractured horizontal rami of mandible in interdental plate.

Fig. 3: Pre-operative X-ray

Fig. 4 and 5: Both the K-wires before advancing from the proximal fragment into distal fragment to bring perfect occlusion

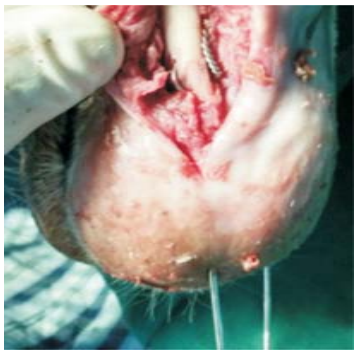

Fig. 6: Cerclage wiring done after fracture reduction and pinning

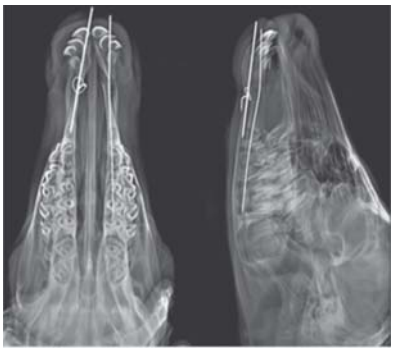

Fig. 7: Post-operative lateral and V-D view

Fig. 8: Reduced fracture

Fig. 9: Few days after surgery with almost normal mobility

a - Brand of Intas Animal Health, Ahmedabad

Treatment

The calf was given Ceftriaxone (Intacef[a]) 500mg IV, 1ml Meloxicam (Melonex[a]) and was subjected to general anesthesia with Ketamine @ 5mg/kg b. wt. and Diazepam 0.5mg /kg b. wt. intravenously and given top-ups as required. The oral cavity at the fractured site was lavaged with Normal saline and 5% Povidone iodine slowly by keeping the jaw in lowered position so as to prevent aspiration of lavaged contents.

A 1.5mm k-wire was passed through the proximal fragment rostrally so that it comes out in front of mouth and the same K-wire was driven caudally into distal fragment of corresponding rami and advanced cranially. Both pins were introduced simulataneously into distal fragments so that the hanging fractured part was reduced and raised to bring proper appostion of fractured ends (Fig. 4 and 5). The fractured ends of right ramus was approached with

www.IJour.net
Members Copy, Not for Commercial Sale
Downloaded From IP - 3.145.188.160 on dated 4-May-2024

skin incision ventrally and stabilized a hemicerclage wiring using 20G stainless steel wire (Fig. 6). The muscle and subcutaneous tissue were sutured with simple interrupted sutures using vicryl-0 and skin closed with nylon using simple interrupted sutures. The K-wires were cut close to skin and owner was advised to get them removed after thirty days with instructions to lavage the oral cavity with warm normal saline solution daily along with Ceftriaxone 500mg, IM daily for one week and Meloxicam 1ml IM for four days.

The calf was discharged the same day after surgery (Fig. 7) and reported started suckling its mother about 6-8 hrs after surgery and had an uneventful recovery after two weeks (Fig. 8).

Discussion

Reduction of both the fragments at the same time by passing the K-wire simultaneously into distal fragments asisted in achieving good apposition of fractured fragments easily (Fig. 7). Reducing the fracture - one side followed by other makes it difficult in achieving proper reduction and occlusion of both fractures.

A good immobilization and appropriate reduction of fracture achieved by use of K-wires and hemicerclage in the present case was evident as the calf started suckling milk within 6-8 hours after surgery. Repair by intra-medullary pinning and cerclage resulted in proper stabilization of fracture fragments.

Acknowledgement

The authors are thankful to the Director of Animal Husbandry, Andhra Pradesh for providing the necessary facilities to carry out the work.

References

Aksoy, O., Ozaydin, I., Kilic, E., Ozturk, S., Gungor, E., Kurt, B. and Oral, H. **(2009).** Evaluation of fractures in calves due to forced extraction during dystocia: 27 cases (2003-2008). *Kafkas Univ Vet Fak Derg*. ***15*:** 339-44.

Desrochers Mandibular Fractures in Cattle **(2011)**. www. acvs. org/files/ proceedings/ 2011/data/papers/218.pdf page 657-659.

Tyagi, R.P.S. and Jit Singh **(1996).** *Ruminant Surgery*, CBS Publishers and Distributors. p. 369-70.

NVF

NATIONAL VETERINARY FOUNDATION

invites all

Companion Animal Vets

for

Indian VETopia

9-11th February' 2018

Kingdom of Dreams

Gurugram, Haryana

For details, please contact :
NVF Secretariat
Dr. R.T. Sharma/ Dr. Umesh Karkare
Pet Hospital an!@d Boarding Shelter
C 9/7, Masudpur Mkt.
Vasant Kunj, New Delhi-110070
Phone: 011-26895737; 26136435
Mobile: 09810036254
E-mail: info@nvf.org.in

www.IJour.net
Members Copy, Not for Commercial Sale
Downloaded From IP - 3.145.188.160 on dated 4-May-2024